

Medial patellofemoral ligament anatomy: is it a predisposing factor for lateral patellar dislocation?

Victor de Oliveira · Vanessa de Souza · Ricardo Cury ·
Osmar Pedro Camargo · Osmar Avanzi ·
Nilson Severino · Patricia Fucs

Received: 11 February 2014 / Accepted: 9 April 2014
© Springer-Verlag Berlin Heidelberg 2014

Abstract

Purpose Because the medial patellofemoral ligament (MPFL) is the primary restraint to lateral dislocation of the patella, we aimed, in this controlled study, to verify whether the MPFL with different measurements could be considered another predisposing factor for patellar dislocation.

Methods A group of 100 consecutive individuals without the criteria for patellar dislocation (trochlear dysplasia, patella alta and lateral patellar tilt) was recruited as a control group and underwent magnetic resonance imaging (MRI) study and another group of 50 patients with patellar instability. Femoral condyles, interepicondylar distance, length and thickness of the MPFL were measured.

Results In the control group, the MPFL was 38–60 mm long. Individuals with patellar instability who had no episode of patellar dislocation had a 4.11-mm longer ligament than controls ($p=0.032$), while patients with instability with a previous history of dislocation had a 13.54-mm longer MPFL than controls ($p<0.001$). Thickness of the MPFL at the patellar insertion was lower in individuals with patellar instability with a history of dislocation ($p<0.001$). An instability coefficient (IC) less than 1.3 indicates that the MPFL is insufficient.

Conclusions Individuals with patellar instability and previous patellar dislocation present with longer MPFL when compared to controls, and an associated IC less than 1.3 can be considered a predisposing factor for patellar dislocation. Treatment of patellar instability is a challenge, and it is

difficult to identify what is the predisposing factor. This study has verified the measurements of the MPFL for the first time and presents values of thickness and length that can be considered as indications for surgical reconstruction.

Level of evidence: III.

Keywords Patella · Patellar ligament · Joint instability · Knee

Introduction

Patellar instability results in subluxation and dislocation of the patella, causing pain and functional impairment, both in athletes and non-athletes. A number of factors are involved in this instability: trochlear dysplasia in 85–96 % of cases, increased lateral patellar tilt in 83 % of cases, patella alta in 24 % and an increase in the distance between the tibial tuberosity and the centre of the trochlear groove (TT-TG) in 56 % of cases as well as other, less frequent problems [1–6]. These anatomical changes are described in the literature as “factors for patellar instability”.

The congruence of the patellofemoral joint is maintained by static and dynamic stabilising structures. The medial patellofemoral ligament (MPFL) is the primary passive soft tissue restraint to lateral dislocation of the patella [7–11]. Based on biomechanical and clinical studies, rupture of the MPFL is an essential lesion in lateral patellar dislocation [8–12].

The MPFL is a retinacular band of tissue located on a lower plane than the vastus medialis oblique muscle. The MPFL has its insertions over the medial upper margin of the patella and in the medial femoral epicondylar region. In the femur, the insertion could also be located between the adductor tubercle and the medial epicondyle [8, 11, 13]. The MPFL is approximately 55 mm in length and between 3 and 30 mm in width. It can bear a force of 208 N before rupturing [8]. The role of the

V. de Oliveira · R. Cury · O. P. Camargo · O. Avanzi · N. Severino ·
P. Fucs (✉)
Orthopaedic and Traumatology, Santa Casa Medical School and
Hospitals, São Paulo, Brazil
e-mail: patricia@fucs.com.br

V. de Souza
Radiology Department, Santa Casa Medical School and Hospitals,
São Paulo, Brazil

MPFL in preventing lateral dislocation of the patella is more marked at between 0 and 30° of knee flexion, when the ligament is more tense [7, 8].

The MPFL is an anatomical structure that is difficult to isolate in cadaveric studies, some of which report that this ligament is not present [11, 14, 15]. However, the MPFL is easily identifiable in magnetic resonance imaging (MRI) studies [3, 5, 13, 16–23]. In the literature, only two studies have correlated the MPFL measurements with other anatomical structures in the knee [14, 23]. In a literature search, no studies were found analysing variations in the MPFL in cases in which factors for patellar instability were identified.

Due to the importance of the MPFL in the stabilisation of the patella, the hypothesis of this study was that an abnormality in the ligament's structure may be a predisposing factor for the occurrence of primary dislocation of the patella and, subsequently, progression to chronicity. This study aimed, therefore, to investigate the morphological characteristics of the MPFL, comparing normal knees with knees with three risk factors for patellar instability: trochlear dysplasia, patella alta and increased lateral patellar tilt. MRI was chosen due to the difficulty in isolating this ligament in cadavers and also because the incidence of abnormal parameters is very low in the general population, e.g. 2 % cited for trochlear dysplasia [2, 16].

The objective of the study was to verify whether individuals with the risk factors for patellar instability (trochlear dysplasia, patella alta and lateral patellar tilt greater than 20°) have altered MPFL measurements, compared to a control group (CG) of normal individuals, and also to verify whether morphological characteristics of the MPFL might be considered a possible predisposing factor for patellar dislocation.

Materials and methods

This was an observational, case-control study carried out in a public hospital. All patients attending the knee clinic between August 2011 and September 2012 and submitted to MRI of the knee were included. All of the patients and control subjects signed informed consent forms for participation, and the study was approved by the Ethics Committee of the Institution.

Patients with fracture sequelae or tumours were excluded, as were those who had undergone knee or leg surgery before admission. Patients with a history of patellar dislocation in the previous 12 months were also excluded, because the oedema of a recent episode of dislocation could interfere with MRI signals and make it difficult to measure the ligament.

Participants were divided into two groups: the CG consisting of patients with diagnoses such as anterior cruciate ligament (ACL) tears, meniscal or femorotibial chondral lesions and no symptoms of patellar instability and the instability group (IG) comprising all cases with anterior knee pain and signs of malalignment of the extensor mechanism. The latter

group was subdivided into two subgroups: the first with patients presenting risk factors for instability, but no patellar dislocation had been reported. This was called the “potential instability” subgroup. The second subgroup, called “objective instability”, contained patients with at least one previous episode of patellar dislocation.

The study group was comprised of 146 patients and 150 knee MRI examinations. Of this group, 25 patients were excluded, leaving 121 patients who were studied, including four cases of bilateral involvement, with a total of 125 knees. In the CG, 88 MRIs were performed and in the IG, 38 were performed, with 19 cases in each subgroup: potential and objective instability. The mean age at the time of the examination was 38.6 years (\pm 15.8), and 66 (54.4 %) were women.

All of the MRI measurements were conducted by two radiologists specialised in musculoskeletal system radiology. As the intra-class correlation coefficient (ICC) between them was higher than 95 %, the mean measurement was registered for statistical analysis.

On MRI, the MPFL was characterised as a band with a focal, continuous thickness, greater than the other portions of the medial patellar retinaculum, and with low signal sequences in proton density, extending from the medial border of the upper part of the patella to the posterior portion of the medial epicondyle of the femur. The route and the patellar and femoral insertions of the MPFL were best evaluated in axial sequences. The route of the MPFL was seen more clearly in the coronal sequences than in the sagittal sequences.

All of the MRI exams were performed in the same manner, with a 1.5 T device (Intera, Phillips), eight-channel coil and proton density-weighted sequences in three planes (sagittal, coronal and axial), with and without fat saturation, using the following parameters: echo time (TE) 1,642, TE 30, matrix 512×256, field of view (FOV) 16×16, slice thickness of 3.5 mm, with an interval of 0.3 mm. During the exam, the knee was placed in a standardised position, in extension, with the patient supine but without any other special positioning. The image analysis was performed on workstations using the PACS/RIS Agfa software.

The following measurements were obtained:

- Size of the lateral and medial femoral condyles, on the sagittal plane, in the section of the longer anteroposterior axis, measuring bone to bone surface (Fig. 1)
- Interepicondylar distance, in the axial and coronal planes (Figs. 2 and 3), at the level of the confluence of the medial collateral ligament, adductor magnus and MPFL insertions
- Patellar height in the sagittal section, according to the Caton-Deschamps index (with values >1.2 indicating patella alta [1, 5])
- Trochlear dysplasia: trochlear depth, measured in the axial section 3 cm proximally to the joint surface

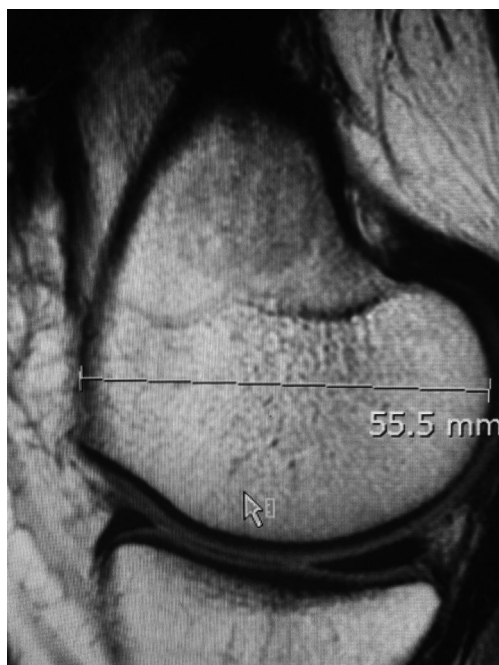

Fig. 1 Measurement of the anteroposterior distance in the medial condyle in the sagittal cut of MRI exam

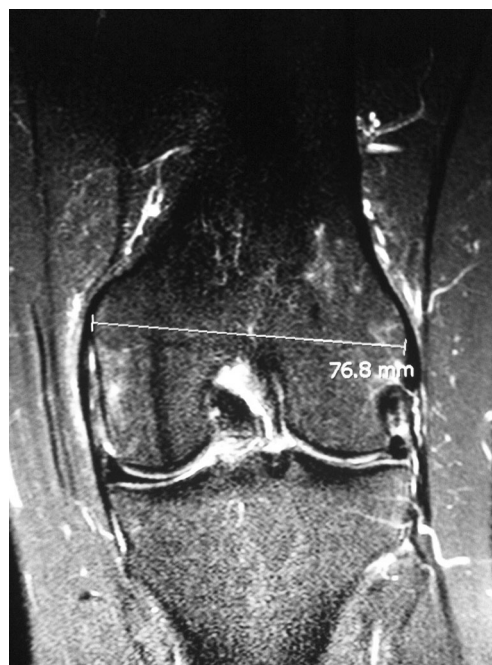

Fig. 3 Measurement of the interepicondylar distance in coronal cut of MRI exam

(<3 mm indicating trochlear dysplasia [3, 5, 16]); ventral trochlear prominence, measured in the sagittal section (>6.9 mm indicating trochlear dysplasia [16]); trochlear groove angle, measured in the axial section, 3 cm above the joint surface (>150° indicating trochlear dysplasia [2, 3, 5]); inclination of the lateral facet, corresponding to the angle of inclination of the lateral facet relative to the coronal plane, tangent to the posterior region of the femoral condyles (<11° indicating trochlear dysplasia [3, 5])

- Ratio of the trochlear facets, medial to lateral, measured in the axial section 3 cm above the joint surface (<0.4 indicating trochlear dysplasia [3, 5, 16])

- Inclination angle of the patella, measured in the axial plane (>20° indicating instability) [1]
- Wiberg patellar classification [24]
- Measurements of the MPFL in millimetres: thickness at 5 mm from the patellar insertion, in the midpoint and at 5 mm to the femoral insertion, full length from insertion to insertion, using the Higuchi et al. technique [22] (Fig. 4)

Qualitative variables were described as relative and absolute frequencies, while quantitative variables were described as means, standard deviations, medians, minimum and

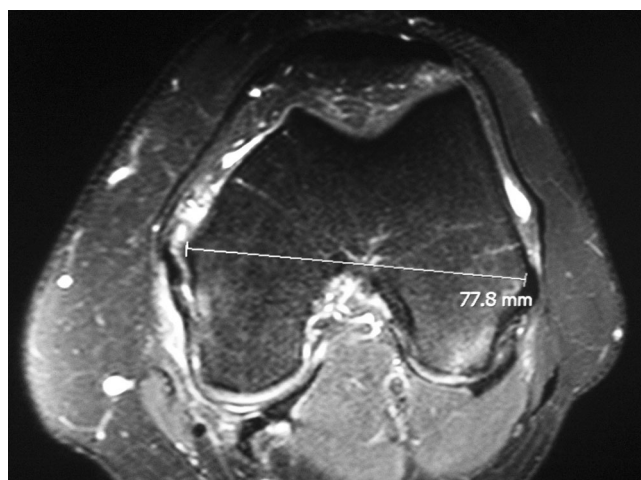

Fig. 2 Measurement of the interepicondylar distance in the axial cut of MRI exam

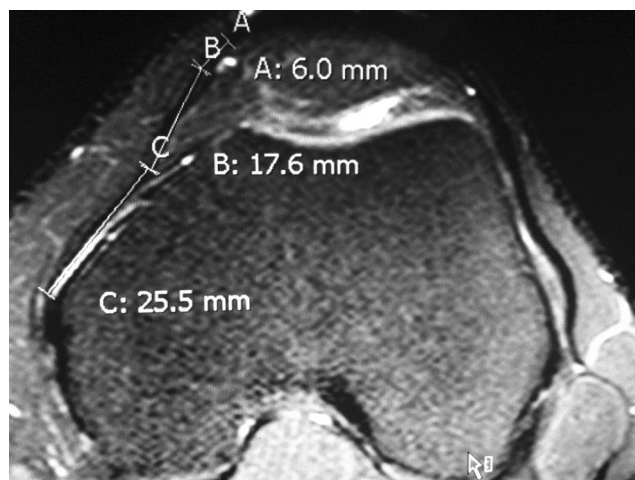


Fig. 4 Measurement of the MPFL full length in the axial cut of MRI exam

maximum values. Pearson's correlation was calculated between the ligament measurements and patient's age, femoral condyle size and epicondylar distance. Student's *t* test was used to determine the association between the measurements and the patient's gender. Analysis of covariance (ANCOVA) was used to determine the personal and femoral condyle characteristics that could influence the ligament measurements, followed by Bonferroni multiple comparisons, to detect any differences in the ligament measurements. SPSS software was used in the statistical analysis, adopting a level of significance of 5 %.

Results

In the CG, MPFL length ranged from 36.1 to 61.8 mm, with a mean of 49.0 mm and thickness of between 0.5 and 3.7 mm at the different measurement points. In the IG, MPFL length ranged from 43.7 to 76.6 mm, with a thickness of between 0.4 and 3.1 mm.

MPFL length correlated inversely with age ($p < 0.001$), with older individuals having shorter ligaments. There was a direct correlation between thickness of the middle third and at the patellar insertion and the size of the medial femoral condyle ($p < 0.05$) and between the femoral insertion and the size of the lateral femoral condyle ($p = 0.021$) (Table 1).

The MPFL was significantly thicker in men than in women ($p = 0.045$) at the femoral insertion. The other measurements were not significantly influenced by sex. Comparing the CG with the subgroups of the IG, with and without any previous episode of patellar dislocation, or objective and potential instability, it was observed that the mean MPFL length and the mean thickness at the patellar insertion were statistically different ($p < 0.001$), regardless of other characteristics that could influence the ligament measurements (Table 2).

MPFL length and thickness at the patellar insertion was significantly different between CG and the subgroups of IG,

potential and objective instability. Cases with potential instability had longer MPFL than the controls (average increase of 4.11 mm) ($p < 0.032$). Even longer lengths were seen in the subgroup with objective instability, i.e. cases with previous episodes of dislocation (average increase of 13.54 mm) ($p < 0.001$). The mean thickness at the patellar insertion was significantly less than in the IG cases with objective instability compared with the CG ($p < 0.001$) (Table 3).

Analysing only the 35 cases with trochlear dysplasia and the 15 cases with patellar lateral inclination over 20° , the mean length of the MPFL was significantly greater than in the CG, and the mean thickness at the patellar insertion was statistically less than that of the controls, independently of previous episodes of patellar dislocation ($p < 0.001$). Based on our findings for MPFL length, any length greater than 60 mm was considered abnormal and insufficient.

To minimise the differences in bone sizes among individuals, a coefficient that would more accurately reflect whether the ligament is longer compared with the condyle's size was calculated. The interepicondylar distance in the axial and coronal planes was chosen, to correlate with MPFL length. The coefficients found ranged from 1.30 to 1.95; the smaller the coefficient, the longer the ligament, in both planes. Values lower than 1.3 indicate insufficient MPFL length to prevent patellar dislocation (Table 4).

Discussion

Although the existence and importance of the MPFL for stabilisation of the patella was first described in 1979 by Warren and Marshall [25], it has only been in recent decades that studies have emerged proving this theory and describing the first techniques for repair and reconstruction of this ligament in the treatment of patellofemoral joint instability [7–9, 14, 15, 26–29]. As in other publications [3, 5, 13, 16–23], it

Table 1 Pearson's correlations (*r*) between age and measurements of the femoral condyles ($n = 125$) and statistical significance (*p*)

Correlation		Total length	Thickness at medial third	Thickness at patellar insertion	Thickness at femoral insertion
Age (years)	<i>r</i>	−0.375	−0.057	0.098	0.038
	<i>p</i>	< 0.001	0.525	0.278	0.672
Lateral femoral condyle size, sagittal plane	<i>r</i>	0.079	0.173	0.151	0.207
	<i>p</i>	0.383	0.054	0.094	0.021
Medial femoral condyle size, sagittal plane	<i>r</i>	0.095	0.196	0.230	0.158
	<i>p</i>	0.294	0.028	0.010	0.079
Interepicondylar distance, axial	<i>r</i>	0.146	0.082	0.093	0.119
	<i>p</i>	0.103	0.361	0.303	0.188
Interepicondylar distance, coronal	<i>r</i>	0.153	0.115	0.130	0.102
	<i>p</i>	0.089	0.203	0.147	0.255

Table 2 Measurements of the MPFL (mm) and correlations with controls, with and without episodes of patellar dislocation

Variable	Groups	Mean	SD	Median	Minimum	Maximum	<i>n</i>	<i>p</i>
Total length	Control	49.04	5.64	48.8	36.1	61.8	87	< 0.001
	Potential instability	53.63	6.97	55.3	43.7	64.6	19	
	Objective instability	63.81	7.98	65.5	51.1	76.6	19	
Thickness at medial third	Control	1.27	0.44	1.2	0.6	3.3	87	0.101
	Potential instability	1.12	0.37	1.1	0.6	1.8	19	
	Objective instability	0.98	0.39	0.9	0.4	2.3	19	
Thickness at patellar insertion	Control	1.71	0.59	1.6	0.7	3.2	87	< 0.001
	Potential instability	1.37	0.72	1.2	0.4	3.1	19	
	Objective instability	0.90	0.40	0.8	0.4	1.9	19	
Thickness at femoral insertion	Control	1.14	0.46	1.1	0.5	3.7	87	0.339
	Potential instability	1.00	0.39	0.9	0.6	2.0	19	
	Objective instability	0.91	0.31	0.9	0.6	2.0	19	

SD standard deviation

was possible to identify the MPFL in all of the MRI exams in our sample.

The results showed that in patients who had never had an episode of patellar dislocation only the length of the MPFL was altered. MPFL length was also changed in individuals with at least one of the criteria for patellar instability, regardless of other variables that might influence the measurements of this ligament. No other study was found measuring the length and thickness of the MPFL in normal individuals and in patients with the criteria of instability and performing the comparisons made here. Therefore, this is the first study to objectively measure, by MRI, MPFL length and thickness in both groups of patients, with and without patellar instability. The values registered here can be used for comparisons with other populations in other settings as the coefficient was normalised to minimise differences in body sizes.

In our results, in individuals with any of the criteria of instability and at least one previous episode of patellar dislocation, the MPFL was around 30 % longer, but with only half the thickness near the point of patellar insertion. These are evident signs of increased risk for patellar dislocation and should be watched carefully in the MRI scans of patients with knee problems as part of routine care, independently of history

of patellar dislocation. Other parameters can be observed on MRI though.

The changes in the MPFL were even more marked in patients with trochlear dysplasia and with patellar lateral inclination over 20°, with longer length and less thickness at the patellar insertion, independently of history of previous patellar dislocation. The conclusion is that in the presence of these two factors, attention should be paid to the MPFL morphology, which will most likely be altered, with patellar instability increasing the risk for dislocation.

In patients of the potential instability group, the MPFL was much longer at 4.11 mm greater than in the CG. This significant difference suggests that the altered ligament is a predisposing factor for dislocation. In the other cases of IG with a history of patellar dislocation (objective instability), the changes in the MPFL were even more marked, with a mean length greater than 13.54 mm and thickness 0.78 mm less than the controls. A temporal relationship is difficult to establish here as the measurements prior to the episode of dislocation were not known (if they were yet abnormal, increasing the risk of dislocation) or the ligament healing after dislocation was insufficient, leading to longer and thinner ligaments. Thus, in patients with abnormal MPFL documented after an episode of

Table 3 Results of the Bonferroni multiple comparison test and association between measurements of the length and thickness of the MPFL (mm) between groups

Variable	Comparison groups	Mean difference	Standard error	<i>p</i>
Total length	Control x potential instability	-4.11	1.59	0.032
	Control x objective instability	-13.54	1.71	< 0.001
	Potential instability x objective instability	-9.43	2.05	< 0.001
Thickness at patellar insertion	Control x potential instability	0.31	0.15	0.126
	Control x objective instability	0.78	0.16	< 0.001
	Potential instability x objective instability	0.47	0.19	0.051

Table 4 Correlation between interepicondylar distance, axial and coronal planes, and the full length of the MPFL, components of the instability coefficient (IC)

Variable	Group	Mean	SD	<i>n</i>	<i>p</i>	NI (95 %)	
						Inferior	Superior
Axial IC	Control	1.63	0.16	87	< 0.001	1.30	1.95
	Potential instability	1.41	0.19	19			
	Objective instability	1.17	0.17	19			
Coronal IC	Control	1.60	0.16	87	< 0.001	1.28	1.92
	Potential instability	1.39	0.18	19			
	Objective instability	1.15	0.16	19			

Statistical method: ANCOVA

n number of subjects, *NI* normal interval

patellar dislocation, surgical treatment should be considered, even after the first episode.

This indication for patients with previous dislocation is corroborated by the results of other studies [19, 22, 28, 29], which conclude that after the first episode of patellar dislocation the MPFL becomes insufficient, predisposing to recurrence. A study by Lewallen et al. [4], in 2013, showed that among individuals under 18 years of age with trochlear dysplasia, after an acute dislocation event and conservative treatment, 69 % relapsed and would therefore benefit from early surgical treatment.

Although the MPFL has shown to be thinner throughout its length in individuals with any of the criteria for instability, it was right next to the patella that a significant difference in thickness from the CG was seen. This suggests that this is the most frequent site of rupture. Some studies have confirmed this hypothesis [3, 13, 20, 30, 31]; however, others have reported the femoral insertion as the most frequent site of MPFL rupture [19, 21, 28, 29, 32]. Balcarek et al. [19], in 2010, in a study of acute patellar dislocations, observed that in patients with trochlear dysplasia and patella alta injuries were predominantly near the patella or the femur, with concomitant lesions in the patella and femur. Few patients had lesions in the central region of the ligament. Patients with an increase of more than 20 mm in the TT-TG had lesions near the patella. However, Weber-Spickschen et al. [21], in 2011, analysing 59 patients with acute patellar dislocation, found no relationship between injury site and morphology of the trochlea.

Dejour et al. [1], an experienced group of researchers, stated that there are four factors of symptomatic patellar instability: trochlear dysplasia, patellar lateral tilt greater than 20°, patella alta and TT-TG of more than 20 mm [33]. However, an important fifth determinant of patellar instability was found: a longer MPFL—as observed in patients with the same predisposing factors for dislocation but no episodes of dislocation—could represent, in our view, not a result of the event of dislocation, but a risk factor.

To establish whether increased MPFL length is the cause or effect of the instability can only be done, in the authors' view, by a longitudinal study, with clinical and sequential MRI measurements, measuring ligaments from the first symptoms

and signs of patellofemoral instability, such as anterior knee pain, and after the patellar episode of dislocation.

In face of a patient with patellar dislocation risk or history, it is useful to calculate the coefficient of instability proposed here. This coefficient, when less than 1.30 in the axial section and less than 1.28 in the coronal view, indicates reconstruction surgery, and many different techniques [34–36] can be chosen.

Conclusion

Individuals with risk factors for patellar instability (presence of trochlear dysplasia, patella alta and patellar tilt greater than 20°) and previous patellar dislocation present abnormally longer MPFLs when compared to controls and to individuals with risk factors for patellar instability and no history of patellar dislocation. Furthermore, when these abnormalities are associated with a coefficient of instability less of than 1.3, longer MPFL can and should be considered a predisposing factor for patellar dislocation.

References

1. Dejour H, Walch G, Nove-Josserand L, Guier C (1994) Factors of patellar instability: an anatomic radiographic study. *Knee Surg Sports Traumatol Arthrosc* 2(1):19–26
2. Bollier M, Fulkerson JP (2011) The role of trochlear dysplasia in patellofemoral instability. *J Am Acad Orthop Surg* 19(1):8–16
3. Diederichs G, Issever AS, Scheffler S (2010) MR imaging of patellar instability: injury patterns and assessment of risk factors. *Radiographics* 30(4):961–981
4. Lewallen LW, McIntosh AL, Dahm DL (2013) Predictors of recurrent instability after acute patellofemoral dislocation in pediatric and adolescent patients. *Am J Sports Med* 41(3):575–580
5. Charles MD, Haloman S, Chen L, Ward SR, Fithian D, Afra R (2013) Magnetic resonance imaging-based topographical differences between control and recurrent patellofemoral instability patients. *Am J Sports Med* 41(2):374–384
6. Arendt EA (2005) Anatomy and malalignment of the patellofemoral joint: its relation to patellofemoral arthrosis. *Clin Orthop Relat Res* 436:71–75

7. Feller JA, Amis AA, Andrich JT, Arendt EA, Erasmus PJ, Powers CM (2007) Surgical biomechanics of the patellofemoral joint. *Arthroscopy* 23(5):542–553
8. Amis AA, Firer P, Mountney J, Senavongse W, Thomas NP (2003) Anatomy and biomechanics of the medial patellofemoral ligament. *Knee* 10(3):215–220
9. Nomura E, Inoue M, Osada N (2005) Anatomical analysis of the medial patellofemoral ligament of the knee, especially the femoral attachment. *Knee Surg Sports Traumatol Arthrosc* 13(7):510–515
10. Philippot R, Chouteau J, Wegrzyn J, Testa R, Fessy MH, Moyon B (2009) Medial patellofemoral ligament anatomy: implications for its surgical reconstruction. *Knee Surg Sports Traumatol Arthrosc* 17(5):475–479
11. Aragão JA, Reis FP, de Vasconcelos DP, Feitosa VL, Nunes MA (2008) Metric measurements and attachment levels of the medial patellofemoral ligament: an anatomical study in cadavers. *Clinics* 63(4):541–544
12. LeGrand AB, Greis PE, Dobbs RE, Burks RT (2007) MPFL reconstruction. *Sports Med Arthrosc* 15(2):72–77
13. Guerrero P, Li X, Patel K, Brown M, Busconi B (2009) Medial patellofemoral ligament injury patterns and associated pathology in lateral patella dislocation: an MRI study. *Sports Med Arthrosc Rehabil Ther Technol* 1(1):17
14. Reider B, Marshall JL, Koslin B, Ring B, Girgis FG (1981) The anterior aspect of the knee joint. *J Bone Joint Surg Am* 63(3):351–356
15. Conlan T, Garth WP Jr, Lemons JE (1993) Evaluation of the medial soft-tissue restraints of the extensor mechanism of the knee. *J Bone Joint Surg Am* 75(5):682–693
16. Pfirrmann CW, Zanetti M, Romero J, Hodler J (2000) Femoral trochlear dysplasia: MR findings. *Radiology* 216(3):858–864
17. Dirim B, Haghighi P, Trudell D, Portes G, Resnick D (2008) Medial patellofemoral ligament: cadaveric investigation of anatomy with MRI, MR arthrography, and histologic correlation. *AJR Am J Roentgenol* 191(2):490–498
18. Starok M, Lenchik L, Trudell D, Resnick D (1997) Normal patellar retinaculum: MR and sonographic imaging with cadaveric correlation. *AJR Am J Roentgenol* 168(6):1493–1499
19. Balcarek P, Ammon J, Frosch S, Walde TA, Schüttrumpf JP, Ferlemann KG et al (2010) Magnetic resonance imaging characteristics of the medial patellofemoral ligament lesion in acute lateral patellar dislocations considering trochlear dysplasia, patella alta, and tibial tuberosity-trochlear groove distance. *Arthroscopy* 26(7):926–935
20. Kepler CK, Bogner EA, Hammoud S, Malcolmson G, Potter HG, Green DW (2011) Zone of injury of the medial patellofemoral ligament after acute patellar dislocation in children and adolescents. *Am J Sports Med* 39(7):1444–1449
21. Weber-Spickschen TS, Spang J, Kohn L, Imhoff AB, Schottle PB (2011) The relationship between trochlear dysplasia and medial patellofemoral ligament rupture location after patellar dislocation: an MRI evaluation. *Knee* 18(3):185–188
22. Higuchi T, Arai Y, Takamiya H, Miyamoto T, Tokunaga D, Kubo T (2010) An analysis of the medial patellofemoral ligament length change pattern using open-MRI. *Knee Surg Sports Traumatol Arthrosc* 18(11):1470–1475
23. Santos Neto A, Brito MBS, Severino FR, Campos LRA, Nico MAC, Oliveira VM et al (2012) Estudo da articulação patelofemoral por ressonância magnética: a variação da morfologia do ligamento patelofemoral medial [Study on the patellofemoral joint using magnetic resonance imaging: morphological variation of the medial patellofemoral ligament]. *Rev Bras Ortop* 47(2):204–209
24. Wiberg G (1941) Roentgenographic and anatomic studies on the femoropatellar joint: with special reference to chondromalacia patellae. *Acta Orthop* 12(1–4):319–410, Available via: <http://www.deepdyve.com/lp/informa-healthcare/roentgenographs-and-anatomic-studies-on-the-femoropatellar-joint-with-n8Np7ClseO>. Accessed 26 June 2013
25. Warren LF, Marshall JL (1979) The supporting structures and layers on the medial side of the knee: an anatomical analysis. *J Bone Joint Surg Am* 61(1):56–62
26. Gomes JLE, Marczyk LRS, César PC, Jungblut CF (2003) Reconstrução do ligamento patelofemoral medial: sua indicação na luxação da patela [Medial patellofemoral ligament reconstruction: indications in chronic patellar instability]. *Rev Bras Ortop* 38(1/2):56–66
27. Ellera Gomes JL (1992) Medial patellofemoral ligament reconstruction for recurrent dislocation of the patella: a preliminary report. *Arthroscopy* 8(3):335–340
28. Sallay PI, Poggi J, Speer KP, Garrett WE (1996) Acute dislocation of the patella. A correlative pathoanatomic study. *Am J Sports Med* 24(1):52–60
29. Nomura E (1999) Classification of lesions of the medial patellofemoral ligament in patellar dislocation. *Int Orthop* 23(5):260–263
30. Camanho GL, Viegas AC (2003) Estudo anatômico e artroscópico do ligamento femoropatellar medial [Anatomic and arthroscopic study of the medial femoropatellar ligament]. *Acta Orthop Bras* 11(3):145–149
31. Elias DA, White LM, Fithian DC (2002) Acute lateral patellar dislocation at MR imaging: injury patterns of medial patellar soft-tissue restraints and osteochondral injuries of the inferomedial patella. *Radiology* 225(3):736–743
32. Sillanpää PJ, Peltola E, Mattila VM, Kiuru M, Visuri T, Pihlajamäki H (2009) Femoral avulsion of the medial patellofemoral ligament after primary traumatic patellar dislocation predicts subsequent instability in men: a mean 7-year nonoperative follow-up study. *Am J Sports Med* 37(8):1513–1521
33. Arendt EA, Dejour D (2013) Patella instability: building bridges across the ocean, a historic review. *Knee Surg Sports Traumatol Arthrosc* 21:279–293
34. Matthews JJ, Schranz P (2010) Reconstruction of the medial patellofemoral ligament using a longitudinal patellar tunnel technique. *Int Orthop* 34:1321–1325
35. Wang C, Ma L, Zhou J, Ji G, Wang H, Wang F, Wang J (2013) Double-bundle anatomical versus single-bundle isometric medial patellofemoral ligament reconstruction for patellar dislocation. *Int Orthop* 37:617–624
36. Ntagiopoulos PG, Sharma B, Bignozzi S, Lopomo N, Colle F, Zaffagnini S, Dejour D (2013) Are the tubular grafts in the femoral tunnel in an anatomical or isometric position in the reconstruction of medial patellofemoral ligament? *Int Orthop* 37:1933–1941